

**PATIENT**

Peanut Murphy

**SPECIES**

Canine

**BREED**

Pitbull

**SEX**

Male Neutered

**AGE**

2015

**WEIGHT**

67lbs

**INTERPRETED BY**

Maggie Machen Lamy,  
 DVM, DACVIM  
 (Cardiology)

**IMAGING PERFORMED BY**

Rebekah Jakum, CVT,  
 ARDMS/RVT

**HOSPITAL NAME**

Mt. Airy Animal  
 Hospital

**REFERRING VET**

Dr. Riley

**INVOICE**

46762

**DATE**

2/9/26

**PRESENTING CLINICAL SIGNS**

History: Grade 2/6 heart murmur. CXR showed mild atrial enlargement, hepatomegaly. Assess prior to anesthesia.

**ECHOCARDIOGRAM FINDINGS**

2D, m-mode, color flow and doppler imaging is available. Mild diffuse thickening of mitral valve leaflets with no prolapse into the left atrial lumen. Mild eccentric mitral regurgitation with no left atrial dilation (LA:Ao <1.4). Normal MR velocity. Normal LV diameter with adequate myocardial function. The tricuspid valve appears mildly thickened with no significant tricuspid regurgitation. Normal right atrial and ventricular diameter and morphology indicating no overt evidence of pulmonary arterial hypertension. The pulmonic and aortic valves are normal in morphology and mobility. Normal pulmonic and aortic outflow velocities with laminar flow. No obvious aortic and trace pulmonic insufficiency. No pericardial or pleural effusion noted. No obvious cardiac masses.

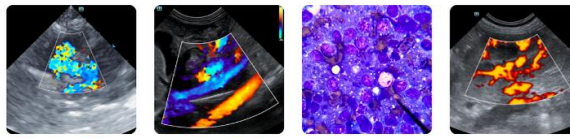
**CARDIAC CHART**

CANINE CARDIAC PARAMETERS	MR VMAX (m/s)	TR VMAX (m/s)	LA/AO (Boon method)	LA/AO (Heart Base; Swe)	FS (%)	EF (%)	EPSS (cm)
<b>NORMAL PARAMETER</b>	4.5-5.5	<2.7	1.3	<1.6	28-40	40-100	<0.6
<b>PATIENT</b>	5.4	NA	NM	1.3	36	66	0.5
CANINE CARDIAC PARAMETERS	HR (BPM)	AV VMAX (m/s)	PV MAX (m/s)	BODY WEIGHT (kg)	LA 2D short axis Base view (cm)	LVIDd Avg; 2D and m-mode short axis (cm)	LVIDs Avg; 2D and m-mode short axis (cm)
<b>NORMAL PARAMETER</b>	50-100	0.7-1.7	0.7-1.6	BELOW	BELOW	BELOW	BELOW
<b>PATIENT</b>		1.4	0.8	30.4	2.4	4.3	2.8
*Normal chamber parameters expressed as a mean value				3	1.27 (5.3)	2.46 (2.46)	1.36 (5.5)
<b>BODY WEIGHT DEPENDENT PARAMETERS</b>				5	1.40 (4.5)	2.74 (5.2)	1.60 (4.7)
Adapted from June Boon, Veterinary Echocardiography, 1998 Rishniw M and Hollis NE, J Vet Intern Med 2000; 14:429-435 Hansson et al, Vet Rad and Ultrasound 2002 Bonagura et al. Echocardiography: principles of interpretation, Vet Clin North Am 15:1177, 1995				10	1.50 (3.8)	3.27 (3.5)	2.06 (3.1)
				15	1.83 (2.0)	3.71 (2.4)	2.43 (2.1)
				20	2.02 (1.9)	4.14 (2.2)	2.80 (2.0)
				25	2.18 (2.4)	4.48 (2.9)	3.10 (2.5)
				30	2.33 (3.3)	4.83 (3.9)	3.39 (3.4)
				35	2.48 (4.3)	5.17 (5.0)	3.69 (4.5)
				40	2.62 (5.2)	5.48 (6.1)	3.96 (5.4)
				50	2.88 (7.1)	6.07 (8.3)	4.46 (7.4)

**INTERPRETATION OF THE FINDINGS & FURTHER RECOMMENDATIONS**

Chronic degenerative valve disease causing mild mitral regurgitation. Lack of significant left atrial enlargement indicates the current risk for complication is low. No concurrent issues such as systolic dysfunction or pulmonary hypertension are noted in this study.

No cardiac medications are clearly indicated, as no benefit has been shown to providing therapy for dogs in stage B1. Omega fatty acid supplementation and mild salt restriction may be of



**PATIENT**

Peanut Murphy

**SPECIES**

Canine

**BREED**

Pitbull

**SEX**

Male Neutered

**AGE**

2015

**WEIGHT**

67lbs

**INTERPRETED BY**

Maggie Machen Lamy,  
DVM, DACVIM  
(Cardiology)

**IMAGING PERFORMED BY**

Rebekah Jakum, CVT,  
ARDMS/RVT

**HOSPITAL NAME**

Mt. Airy Animal  
Hospital

**REFERRING VET**

Dr. Riley

**INVOICE**

46762

**DATE**

2/9/26

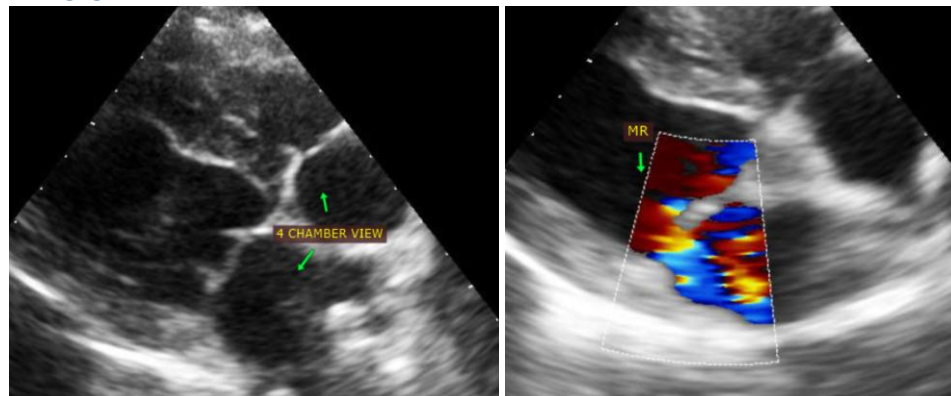
some long-term benefit. Monitor for development of a progressive cough, labored breathing, exercise intolerance or collapse episodes.

Assessment of progression in the future will help predict long term prognosis, which is highly variable with stage B1 disease. Many B1 dogs will remain asymptomatic with slow progression for years to come.

No cardiac contraindication for general anesthesia prior to chamber enlargement.

Recommend conservative monitoring with a recheck echocardiogram in 6-12 months to assess rate of progression, sooner if any development of clinical signs in the interim.

**IMAGES**



**The information and recommendations provided are based on the images presented by the referring veterinarian. No evaluation can be communicated regarding pathology that was not visible in the image/video clips provided.**

Thank you for this referral. This report was generated using transcription software, and minor dictation errors may be present. If the clinical or image interpretation does not parallel your findings or if I can be of any further assistance, please contact me.

**Maggie Machen Lamy, DVM**  
**Diplomate of the American College of Veterinary Internal Medicine (Cardiology)**  
info@sonopath.com